Managing Difficult Wounds Secondary to Charcot Deformity with a Novel Total Contact Cast System.

• Michael Petrocelli, DPM- Collier Podiatry, P.A
Naples, FL

Introduction:

Charcot foot deformity is a serious and a possible lower-extremity limb threatening complication of diabetes. During this uncontrolled inflammatory cycle, the Charcot foot is characterized by varying degrees of bone and joint disorganization secondary to underlying neuropathy, trauma, and disruption of bone metabolism. The Charcot foot in diabetes poses many challenges in its diagnosis and management. The classic rocker-bottom foot deformity is a late stage of the deformity and can be avoided by early recognition and management. Off-loading is the most important initial treatment recommendation. Surgery can be helpful in the early stages involving acute fractures of the foot or ankle or in later stages when off-loading is ineffective.[1]

Objective:

The objective of this case series is to evaluate the use of a comprehensive system that addresses both the off-loading needs and wound management needs of the charcot foot patient. The system used in this case series was a total contact cast (TCC) comprised of a clamshell cast with off-loading footplate,* along with an ovine collagen with intact extracellular matrix (CECM)** to manage MMPs[2] and a gentian violet/methylene blue (GV/MB)*** antibacterial foam which was designed to manage bioburden.[3]

Method:

Patients were selected with wounds secondary to diabetic Charcot deformity. The CECM dressings and GV/MB antibacterial foams were changed according to instructions for use. Assessments and measurement of wounds were performed by the clinician weekly.

Conclusion:

The use of a TCC system comprised of a clamshell cast with off-loading footplate along with the advanced wound dressings in this case series were effective in the management of these complex Charcot wounds. The CECM dressing provided an intact, native extracellular matrix which promotes tissue granulation[4] and epithelialization for final wound closure.[5] The GV/MB antibacterial foam dressings helped to facilitate bioburden reduction. This comprehensive off-loading and wound management system resulted in resolution of wounds without complication. Overall patient satisfaction and compliance were also observed.

Case Study 1

Patient: 53 year-old

Past medical history:

- Left foot diabetic foot ulcer of 3 years
- Hypertension, non-insulin dependent diabetes mellitus, and Hepatitis C
- Mid-foot collapse from Charcot deformity
- Chronic osteomyelitis cuboid bone

- Charcot reconstruction
- Internal & external fixation
- Ulcer debridement with dermal graft & negative pressure wound therapy (NPWT)

- Frame removed at 9 weeks
- Patient compliance became an issue
- Ruined NPWT while fishing
- Ruined 2 competitive TCCs while laying tile
- Wound worsened

Week 0
- CECM dressing applied to wound and covered with GV/MB antibacterial foam
- TCC system comprised of a clamshell cast with off-loading footplate
- Off-loading footplate cutout 1 cm larger than wound with each application

Week 4
- Wound improving
- Patient was more compliant with this TCC system comprised of a clamshell cast with off-loading footplate

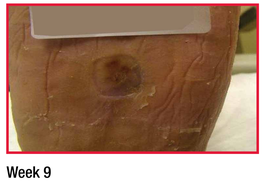

Week 9
- Wound closure
- Transitioned to custom diabetic shoes

Case Study 2

Patient: 54 year-old

Past medical history:

- Hypertension, non-insulin dependent diabetes mellitus, gout
- Posterior tibial tendon rupture with talo-navicular subluxation with a successful repair. Patient admitted to skilled nursing facility with partial weight bearing using a walker with an external fixator.
- Patient fell and twisted foot, breaking mid-foot
- The patient continued to walk on the foot which disrupted the surgical incision
- Diagnosed with osteomyelitis
- External fixator was removed at week 7 and oral antibiotics started

Initial wound management:

- 4 plantar ulcers noted at removal of external fixator
- GV/MB antibacterial foam dressing was applied to each ulcer and draining pin sites and secured with rolled gauze along with a zinc oxide paste compression dressing.
- Heel ulcer measurement: 4.5 cm x 3.7 cm x 0.1 cm

Week 0 *(Figures 1 and 2)*
Heel ulcer measurement:
4.4 cm x 3.6 cm x 0.1 cm
- CECM dressings and GV/MB antibacterial foams were applied to three planter ulcers weekly until resolution in week 3 and only GV/MB antibacterial foam was used on the heel ulcer with eschar weekly
- TCC system comprised of clamshell cast with off-loading footplate was applied
- Off-loading footplate cutout 1 cm larger than heel ulcer with each application

Preparing the off-loading footplate *(Figure 3)*

Applying clamshell cast *(Figure 4)*

Week 1 *(Figure 5)*
Heel ulcer measurement:
3.9 cm x 3.5 cm x 0.1cm
- 14% decrease in heel wound size
- Significant improvement in 3 plantar ulcerations

Week 2
Heel ulcer measurement:
3.5 cm x 3.5 cm x 0.1 cm
- 11% decrease in heel wound size

Week 3
Heel ulcer measurement:
3.6 cm x 3.4 cm x 0.1 cm
- 3 plantar ulcerations have resolved

Week 4
Heel ulcer measurement:
4.0 cm x 3.5 cm x 0.2 cm
- Eschar is loosening

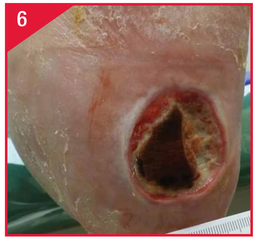

Week 5 *(Figures 6)*
Heel ulcer measurement:
3.3 cm x 3.2 cm x 0.3 cm
- Eschar is loosening

REFERENCES

1. Rogers, L., et al (2011) The Charcot foot in diabetes. Diabetes Care, (34), 2123-2129.
2. Negron L, Lun S, May BC. Ovine forestomach matrix biomaterial is a broad spectrum inhibitor of matrix metalloproteinases and neutrophil elastase. Int Wound J. 2012 Nov 1.
3. United States Food and Drug Administration. "Premarked Notification 510(K) Hydrofera LLC." January 4, 2014. Available at: http://www.accessdata.fda.gov/cdrh_docs/pdf13/K130670.pdf. Accessed January 12, 2015.
4. Tonnesen MG et al. Angiogenesis in Wound Healing. The Society for Investigative Dermatology, Inc. Vol 5, 1; 2000.
5. Pastar I et al. Epithelialization in Wound Healing: A Comprehensive Review. Adv in Skin and Wound Care, Vol 3, 7; 2014.

* FastCast OLS, Distributed by Hollister Incorporated.
** Endoform dermal template, Distributed by Hollister Incorporated.
*** Hydrofera Blue Ready foam, Distribute by Hollister Incorporated.

Financial Disclosure: Dr. Michael Petrocelli received an honorarium from Hollister Incorporated.

923009-0416